

## Case Report

# Managing a maxillary premolar with calcified canals- A case report

Mussab Irfan<sup>1</sup>, Sumyya Saleh<sup>2</sup>, Usman Anwer Bhatti<sup>3</sup>, Shafaq Maqsood<sup>4</sup>, Tariq Akbar<sup>5</sup>, Abdul Haq<sup>6\*</sup>

### Abstract

<sup>1,2,6</sup>FCPS Post Graduation Trainees,  
Department of Operative Dentistry  
Riphah International University

<sup>3</sup>Assistant Professor, Department of  
Operative Dentistry Riphah  
International University

<sup>4</sup>Mphil.Pathology Resident, Liaquat  
University of Medical and Health  
Sciences, Jamshoro

<sup>5</sup>Demonstrator in Department of  
Periodontics Riphah International  
University

\*Corresponding Author's Email:  
[drabdul.haq15@gmail.com](mailto:drabdul.haq15@gmail.com)

**Pulpal calcifications or calcific metamorphosis can present a great challenge for successfully performing root canal treatment. These calcifications can prevent achieving straight line access and glide path to the apical thirds of the roots. Pulpal calcifications can have variable presentations like pulp stones, calcified canals or other calcified masses in the pulpal tissue. There is a range of causative factors including dental trauma, orthodontic treatment, genetic and developmental abnormalities, age and pulpal necrosis. Different methods can be used to overcome this problem during root canal treatment. This article explains the use of Cone beam CT (CBCT) and ultrasonic instruments to remove the calcified tissue and gain access to the root canal system for effectively performing the endodontic treatment.**

**Keywords:** Dental trauma, Pulp calcification, Root canal Treatment, ultrasonic

## INTRODUCTION

Pulp stones are calcified masses in dental pulps of healthy, diseased and even unerupted teeth (Hsieh et al., 2018; McCabe and Dummer, 2012; Ostby, 1957). The prevalence of pulp stones reported in the literature varies between 8-90% based on the population and study methodology (Hsieh et al., 2018; (McCabe and Dummer, 2012; Almohaimede, 2018). Two possible forms of pulp calcifications can exist, a discrete or diffuse and the presence of either one can complicate routine endodontic treatment (Hsieh et al., 2018; McCabe and Dummer, 2012). The exact etiological factors of dental pulp calcification are not properly known but following are the assumed possible causes: age changes, pulp degeneration, circulatory disturbances in pulp, orthodontic tooth movement, idiopathic factors, genetic predisposition (Hsieh et al., 2018; McCabe and Dummer,

2012; Selden, 1989). The first option for treatment of a calcified necrotic tooth is the conventional root canal therapy (Hsieh et al., 2018; Ostby, 1957) but teeth with severe calcification may present challenges with locating and negotiating root canals (McCabe and Dummer, 2012; Almohaimede, 2018). The other options besides nonsurgical endodontic treatment include guided endodontics, surgical root end resection and intentional replantation (McCabe and Dummer, 2012; Krastl et al., 2016). In this case the calcified canals that were not negotiated using the conventional methods were located and negotiated after careful evaluation of Cone Beam CT scan. There are not many case studies on this topic from this part of the globe. Therefore it is thought to bring about certain positive impacts of management of such cases in future. The basic aim of presenting this case

report is to report and discuss this reliable diagnostic and treatment method which will surely benefit others in effectively managing such challenging cases.

## CASE REPORT

A 42 years old male patient reported to the Department of Operative Dentistry, Islamic International Dental Hospital, Islamabad with pain on biting in one of his upper left teeth for the past two weeks. Past dental history revealed a previous attempt of root canal treatment in the same tooth 2 years back which could not be completed due to difficulty in canal location. The previous clinician restored the tooth and advised the patient to keep up with the follow up. Since the patient experienced no symptoms he did not revisit the dentist. Occasionally, the patient took NSAIDs for the discomfort. Chewing was the primary aggravating factor on presentation. Medical history was non-contributory. Patient belonged to a well-educated upper middle class family with no history of smoking or any drug addiction. Extra-oral examination showed no significant finding. On intraoral examination, maxillary left first premolar was restored and was tender to percussion. There was no associated swelling or sinus tract. Both cold test and Electric Pulp Testing produced a negative response. Probing depths were within normal limits. The periapical radiograph revealed a coronal restoration on tooth 24(FDI). The outline of root canals was not visible on the periapical radiograph giving an impression of calcification along with a presence of periapical radiolucency. A diagnosis of previously initiated therapy and symptomatic apical periodontitis was made. After achieving local anesthesia with 2% lidocaine 1:100000 epinephrine (Medicaine) and rubber dam isolation access opening was prepared. Dental loupes were used to enhance visibility. Previous restoration was removed which was already extending up to the pulp chamber level. Even at 11mm depth the canal orifices could not be found at the expected locations (Figure 1-A). To avoid any perforation further excavation was avoided and tooth was temporarised with cavit. A limited FOV-CBCT was advised to further evaluate the root canal morphology and to check if there are any root canals visible on CBCT.

### CBCT: Axial view

Axial slices showed presence of palatal canal from coronal to middle third of the root (Figure 1-B showing axial slice at coronal third, Figure 1-C showing axial slice at middle third and Figure 1-D showing axial slice at apical third). The canal image was dim as compared to the canals in other teeth. Buccal canal was not visible in the axial view at any level of the root. (Arrow indicates the premolar under treatment in Figure 1-A, 1-B and 1-C).

### CBCT: Coronal view

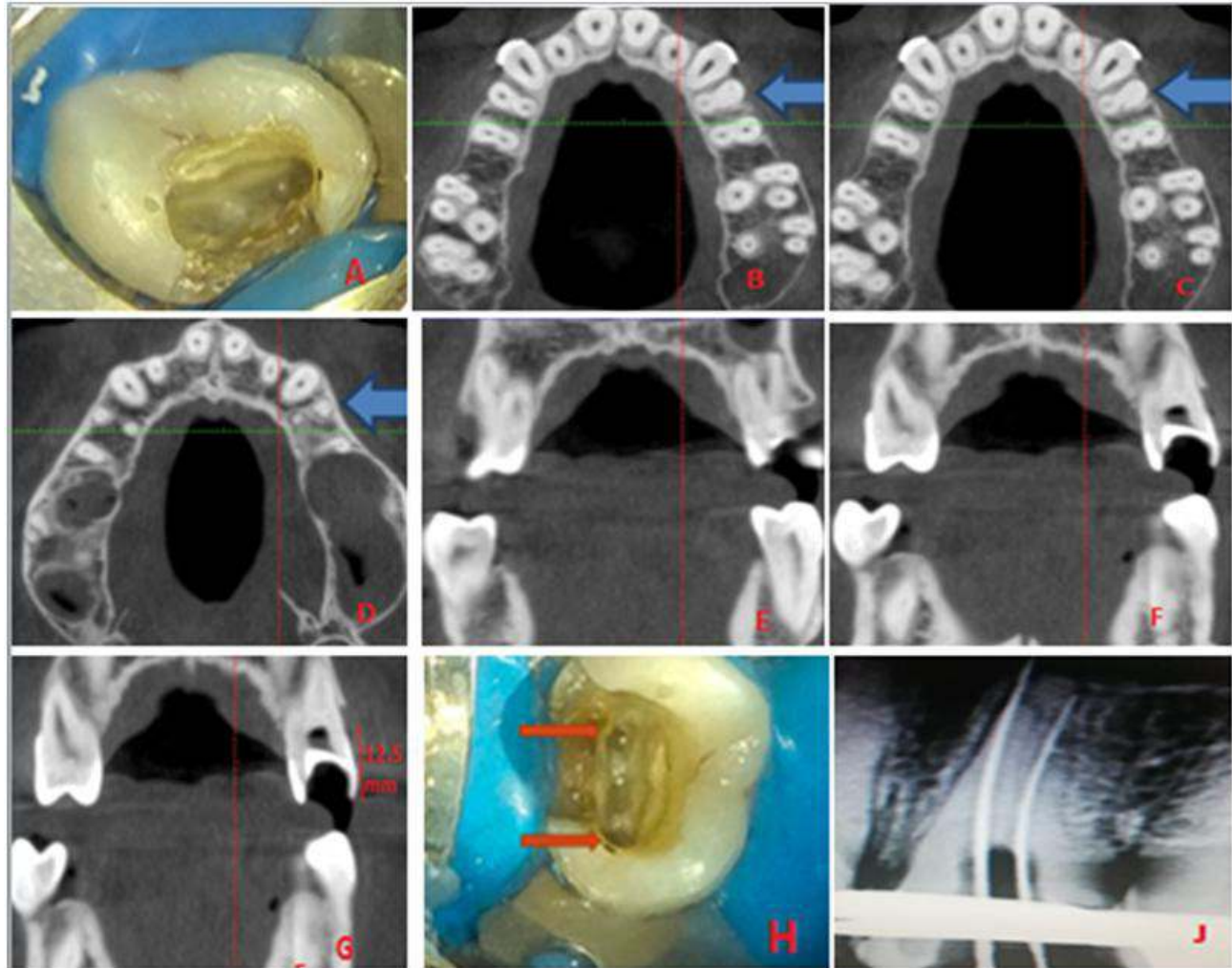
On coronal slices palatal canal image was visible on multiple slices (Figure 1-E) but the buccal canal image was visible on only one coronal slice (Figure 1-F). Periapical radiolucency was associated with the palatal root as well as buccal root.

### 2<sup>nd</sup> Attempt at access opening after CBCT

After administering local anesthesia, using 2% lidocaine 1:100000 epinephrine (Medicaine) and rubber dam isolation the temporary restoration was removed. Dental loupes were used to provide adequate magnification. Ultrasonic scaler tips were used for further troughing deep into the expected location of the canals as interpreted from CBCT. At 12.5mm depth a palatal canal orifice was located and negotiated with a #08 K-file (Mani) (Figure 1-G). At 13mm depth buccal canal orifice was also located and negotiated with a #08 K-file (Mani). Initially the canals were constricted but with slight apical pressure and watch winding motions, apical third of the canals was negotiated (Figure 1-H). Working length was established using Electronic apex locator (Woodpecker) and periapical radiograph (Figure 1-J). Canal preparation was completed with manual instrumentation along with 2.5% Sodium Hypochlorite (Parcan) and 17% EDTA (Septodont). Obturation was done with cold lateral compaction technique. Direct composite restoration (Coltene) was placed after obturation.

## DISCUSSION

The root canal calcifications present a great challenge during root canal treatment (Hsieh et al., 2018). A study suggested that 4-24% of dental traumatic injuries result in pulp canal calcification. About 7-27% of teeth with pulpal calcification develop pulp necrosis and periapical disease (McCabe and Dummer, 2012). Abbot and Yu in their study published in Australian Dental Journal, named this condition as Calcification instead of obliteration (Abbott and Yu, 2007). Yellowish appearance and lack of translucency are common clinical findings related to pulpal calcification. According to a study about 75% of teeth with pulp calcifications don't have any symptoms (Hsieh et al., 2018; McCabe and Dummer, 2012). When it comes to diagnosis it is generally accepted that pulp sensibility tests are not reliable in such cases (McCabe and Dummer, 2012). Tooth color, symptoms and radiographic findings are the major tools for diagnosing such cases (Hsieh et al., 2018; McCabe and Dummer, 2012; Ostby, 1957). Several materials and instruments were used to facilitate overcoming such challenge (Hsieh et al., 2018; Almohaimede, 2018; Ostby, 1957). Root



**Figure 1.** A, Canal orifices not located after removal of previous restoration and achieving 11mm depth into the pulp chamber. B, CBCT image showing axial slice at coronal third of the root. C, CBCT image showing axial slice at middle third of the root. D, CBCT image showing axial slice at the apical third of the root. E, CBCT image showing coronal slice, palatal canal image can be seen. F, CBCT image showing the only coronal slice in which a vague image of buccal canal was seen. G, CBCT image showing the depth at which palatal canal orifice was found after evaluating the CBCT. H, Located palatal and buccal canal orifices at 12.5mm and 13mm respectively. J, Working length radiograph.

canal access in teeth with calcified pulp canals can be very challenging with root perforation and instrument separation as major complications that can occur (McCabe and Dummer, 2012; Ostby, 1957). A study published in International Endodontic Journal advocated the use of dental operating microscope (DOM) for effective management of such cases with calcific pulp changes (Perrin et al., 2014). Chelating agents like EDTA in the form of liquid or paste have been reported to provide assistance in preparing calcified and narrow root canals (Hsieh et al., 2018; McCabe and Dummer, 2012; Ostby, 1957). Ultrasonic instruments are also known to be helpful in removing pulp stones and pulpal calcified masses (Almohaimede, 2018). The pulp chamber and the pulp canal entrances can be subjected to dystrophic calcification after being exposed to  $\text{Ca(OH)}_2$  for a long

period (Hsieh et al., 2018; McCabe and Dummer, 2012). Pulp necrosis may occur due to the reduction of blood supply by this calcification (McCabe and Dummer, 2012; Ostby, 1957; Fuks, 2000). Moreover, the use of sodium hypochlorite (NaOCl) may help in identification a calcified canal through the “champagne bubble test” (McCabe and Dummer, 2012, Johnson, 2009). Several studies proved that the use of the DOM in treating obliterated canals was reported to improve the treatment outcome (Selden, 1989). Furthermore, variously designed burs and ultrasonic tips have been used to facilitate entering the calcified pulp chambers and canals by performing a deep troughing (Hsieh et al., 2018; Selden, 1989). CBCT has proven to be a better radiographic modality as compared to 2D radiography for location and negotiation of calcified root canals as it

provides thinly sliced sections in axial, sagittal, and coronal planes of the examined subject (Reis et al., 2009; Danforth, 2003). According to a study canals that appear completely calcified radiographically could be easily negotiated clinically. This was explained by the difference in the degree of mineralization between the primary and the secondary dentin, where the secondary dentin is considered less radio-dense, which will give the radiographic appearance of a canal with a smaller diameter (Scott and Weber, 1977). In this case a conventional approach to root canal treatment was used first but it went unsuccessful because of failure to locate and negotiate the canal. Afterwards CBCT report was evaluated and used to help in successful location, negotiation and treatment of the narrow calcified root canals as advocated by some established studies (Hsieh et al., 2018; Almohaimede, 2018; Danforth, 2003).

## CONCLUSION

It is possible to treat the teeth with calcified canals if proper equipment and instruments are used along with 3D diagnostic modalities like CBCT. 2D radiographs at different angulations can also play an important role but CBCT is of prime importance in such challenging endodontic cases as it reveals better anatomic detail.

## REFERENCES

- Abbott PV, Yu C (2007). A clinical classification of the status of the pulp and the root canal system. *Australian Dental J.* 1. Mar;52:S17-31.
- Almohaimede AA (2018). The use of cone-beam computed tomography in localizing calcified canals during endodontic treatment. *Saudi Endod. J.*;8(3):217.
- Danforth RA (2003). Cone beam volume tomography: a new digital imaging option for dentistry. *J Calif Dent Assoc.*;31(11):814-5.
- de Toubes KM, de Oliveira PA, Machado SN, Pelosi V, Nunes E, Silveira FF (2017). Clinical approach to pulp canal obliteration: a case series. *Iran. Endod. J.*;12(4):527.
- Fuks AB (2000). Pulp therapy for the primary and young permanent dentitions. *Dent Clin North Am.* Jul;44(3):571-96.
- Hsieh CY, Wu YC, Su CC, Chung MP, Huang RY, Ting PY, et al. (2018). The prevalence and distribution of radiopaque, calcified pulp stones: A cone beam computed tomography study in a northern Taiwanese population. *J. Dent Sci.*;13(2):138-144
- Johnson BR (2009). Endodontic access. *Gen Dent.*;57(6):570-7.
- Krastl G, Zehnder MS, Connert T, Weiger R, Kühl S (2016). Guided endodontics: a novel treatment approach for teeth with pulp canal calcification and apical pathology. *Dental traumatology.* Jun;32(3):240-6.
- McCabe PS, Dummer PM (2012). Pulp canal obliteration: an endodontic diagnosis and treatment challenge. *Int. Endod. J.* Feb;45(2):177-97.
- Oginni AO, Adekoya-Sofowora CA, Kolawole KA (2009). Evaluation of radiographs, clinical signs and symptoms associated with pulp canal obliteration: an aid to treatment decision. *Dental Traumatology.* Dec;25(6):620-5.
- Ostby N (1957). Chelating in root canal therapy. Ethylene-diamine tetraacetic acid for cleansing and widening of root canals. *OdontolTidskr.*;65:3-11.
- Perrin P, Neuhaus KW, Lussi A (2014). The impact of loupes and microscopes on vision in endod. *Int. Endodontic J.* 2 Correspondent author:
- Reis LC, Nascimento VD, Lenzi AR (2009). Operative microscopy—indispensable resource for the treatment of pulp canal obliteration: a case report. *Braz J Dent Traumatol.*;1(1):23-6.
- Robertson A, Andreasen FM, Bergenholtz G, Andreasen JO, Norén JG (1996). Incidence of pulp necrosis subsequent to pulp canal obliteration from trauma of permanent incisors. *J. Endod.* Oct 1;22(10):557-60.
- Scott JN, Weber DF (1977). Microscopy of the junctional region between human coronal primary and secondary dentine. *J Morphol.*;154(1):133-45.
- Selden HS (1989). The role of a dental operating microscope in improved nonsurgical treatment of “calcified” canals. *Oral Surg Oral Med Oral Pathol.*;68(1):93-8.